

## Variations of ostiomeatal complex and its applied anatomy: a CT scan study

H. Mamatha<sup>1</sup>, N.M. Shamasundar<sup>2</sup>, M.B. Bharathi<sup>3</sup> and L.C. Prasanna<sup>4</sup>

<sup>1</sup>Dept. of Anatomy, Kasturba Medical College, Manipal, Karnataka-576104, India

<sup>2</sup>Dept. of Anatomy, J.S.S. Medical College & Hospital, Mysore- 570015, India

<sup>3</sup>Dept. of ENT, J.S.S. Medical College & Hospital, Mysore-570015 India

<sup>4</sup>Dept. of Anatomy, J.J.M. Medical College, Davangere, Karnataka-577004, India.

anatomy1cp@yahoo.com

### Abstract

Stenosis of the ostiomeatal complex, from either the anatomical configuration or hypertrophied mucosa can cause obstruction and stagnation of secretions that may then become infected or perpetuate infection. The surgical interventions of the functional endoscopic sinus surgery are designed to remove the ostiomeatal blockage and to restore normal sinus ventilation and mucociliary function. Hence, the present study was taken up to study the variations in the ostiomeatal complex and its clinical significance. For CT analysis coronal sections of 40 paranasal sinus CT films were collected from the department of ENT. Lateral deviation of the uncinate process was more common with equal incidence in both sexes and with higher incidence on right side. Nasal septum was deviated to the right side more commonly with equal incidence in both sexes. Nearly half of the cases showed agger nasi with higher frequency in males. Concha bullosa was the least common ostiomeatal variant with higher incidence in males with equal incidence on both sides. Preoperative planning for FESS requires high resolution computed tomography (CT) to provide detailed maps, which are used for navigation and the visualization of the anatomical variants that result in sinus disease. As a result, it has become imperative for radiologist and clinicians to improve understanding of ostiomeatal unit.

**Keywords:** Ostiomeatal complex, paranasal sinuses, sinusitis, computed tomography imaging, agger nasi.

### Introduction

Throughout the history of medicine numerous attempts have been made to illuminate and examine the inside of various hollow cavities located within the body. The introduction of the endoscope as a tool to help sinus surgery along with the philosophy of aerating and restoring mucociliary clearance has stimulated interest in both the anatomy and pathophysiology of the paranasal sinuses (Jones, 2002). No consensus exists to define exact anatomic descriptions of the borders and margins of the ostiomeatal complex (Stamberger & Kennedy, 1995). In the present study, the concept developed by Stamberger and Kennedy was adopted defining ostiomeatal complex as a functional unit of the anterior ethmoid complex representing the final common pathway for drainage and ventilation of the frontal, maxillary and anterior ethmoid sinuses (Freitas & Boasquevisque, 2008).

The blockade in the ostiomeatal complex (OMC) leads to impaired drainage of maxillary, frontal and anterior ethmoid sinuses thus causing chronic sinusitis. Thus, this study re-emphasized the concept that ostiomeatal complex is the key factor in the causation of chronic sinusitis. Dua *et al.* (2005) reported that removal of disease in ostiomeatal complex region is the basic principle of functional endoscopic sinus surgery (FESS) which is best appreciated on CT scan. In addition, Stamberger and Hawke (1993) have shown that CT examination of the paranasal sinuses will provide an anatomic road map of the paranasal sinuses to identify

the presence of significant anatomic abnormalities, the location and severity of the disease and exact location of the obstruction.

### Materials and methods

Coronal sections of 40 paranasal sinus CT films were collected from the department of ENT.

*Inclusion criteria:* Adult patients presenting with history of nasal obstruction and headache, who are subjected to radiological investigations after a clinical examination and diagnosis as sinusitis were included for the study.

*Exclusion criteria:* Patients with previous alteration of the paranasal sinus anatomy due to facial trauma, benign tumours of the sinonasal mucosa and previous sinus surgery were excluded from the study.

*Method:* The CT scan is the gold standard investigation in all sinus diseases and it gives detailed bony anatomy of the ostiomeatal area and serves as a roadmap for the operating surgeon. The coronal plane is the preferred imaging plane that best displays the ostiomeatal unit. All CT scans were obtained with Siemens Somatom AR scanner. After obtaining the preliminary lateral topogram of the skull, the area of scanning was defined to include the region from root of frontal sinus upto the hard palate. Coronal sections were performed with the patients in prone position, with extended neck and the plane perpendicular to the infraorbitomeatal line. The sections

were taken with slice thickness of 5 mm. The scans thus generated were photographed at appropriate window widths and window level. They were analysed for anatomical variations and mucosal abnormalities.

*Table 1. Reported prevalences of anatomic variations*

Authors	Agger nasi cell	Haller's cell	Deviated uncinete process	Concha bullosa	Nasal septal deviation
Zinreich <i>et al.</i> (2003)	Nearly all	10%	3%	36%	21%
Bolger <i>et al.</i> (1991)	98.5%	45.1%	-	53%	18.8%
Lloyd (1990)	3%	2%	16%	14%	-
Scribano <i>et al.</i> , (1993)	-	24%	-	67%	-
Wanamaker (1996)	-	20%	45%	30%	20%
Tonai & Baba (1996)	86.7%	36%	-	28%	-
Yousem (1993)	-	10-45%	-	34-53%	-
Pinas IP <i>et al.</i> (2000)	Nearly all	3%	4.5%	73%	80%
Present study	50%	17.5%	65%	15%	65%

**Statistical analysis:** Data will be analyzed in terms of the number, and percentage of the variations of the ostiomeatal complex. Cross tabulations will be done to study the variations according to side and sex. Chi-square test will be applied to assess the significance of association between the side and variations.

**Results**

Different types of anatomical variants present distinct relations with either clinical or tomographic sinus disease as depicted in the table 1. In the present study of the position of nasal septum, 6 (30%) CTs showed centralized nasal septum, 5 (25%) showed left side deviation and 9 (45%) had right side deviation of the nasal septum. The various types of uncinete process in 40 sections (20 CTs) included medially bent uncinete process in 10 (25%), of which 6 were males and 4 were females. Laterally bent uncinete process was seen in 16 (40%) CTs, of which 11 were males and 5 were females. Centralised uncinete process was seen in 14 (35%), of which 9 were males and 5 were females.

Fig.1 shows other variants of ostiomeatal complex; Agger nasi cells present in 20 (50%) cases (14 males & 6 females) and absent in rest 20 (50%) cases. Haller's cells were present in 7 (17.5%) cases, (3 males & 4 females) and absent in 33 (82.5%) cases. Concha bullosa was

present in 6 (15%) cases and absent on 34 (85%) cases. Accessory maxillary ostia were noted in 9 (22.5%) cases and absent in 31 (77.5%) cases. CT evaluation of mucosal abnormalities in different sinuses were noted.

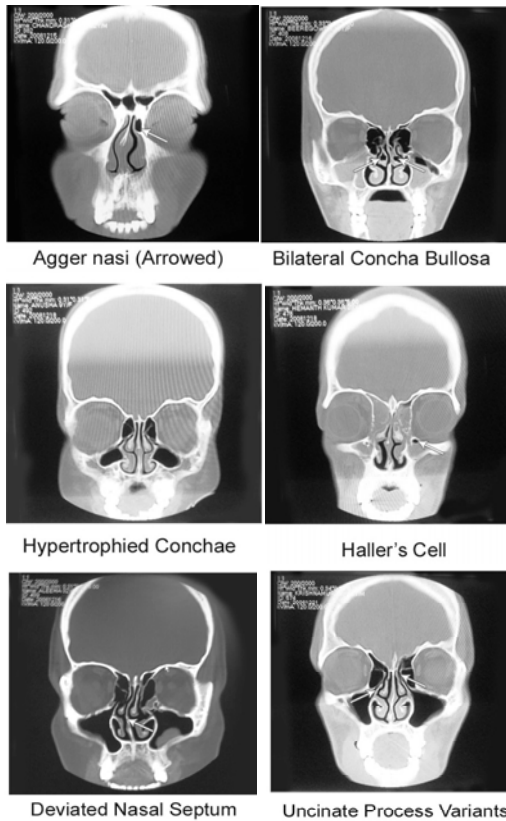
Mucosal thickening was observed in maxillary sinus 27 (67.5%) cases, followed by ethmoidal sinus 13 (32.5%) cases and frontal sinus 10 (25%) cases, while in 4 (10%) cases showed absence of frontal sinus (Graph 1,2 &3).

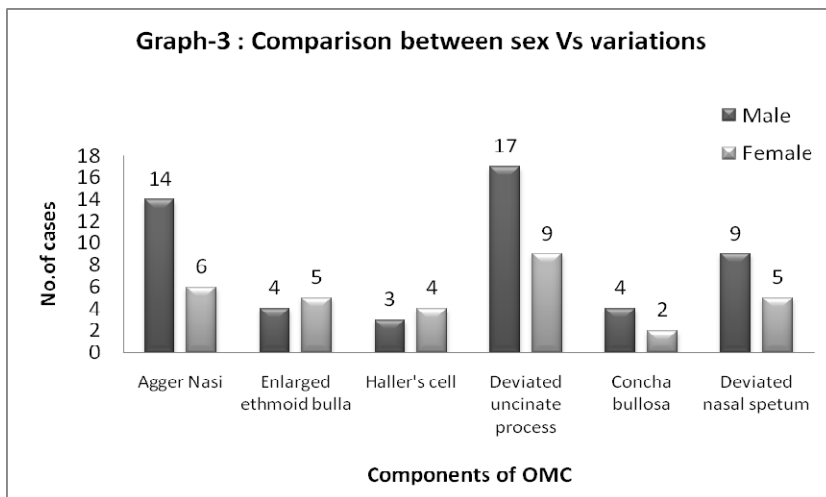
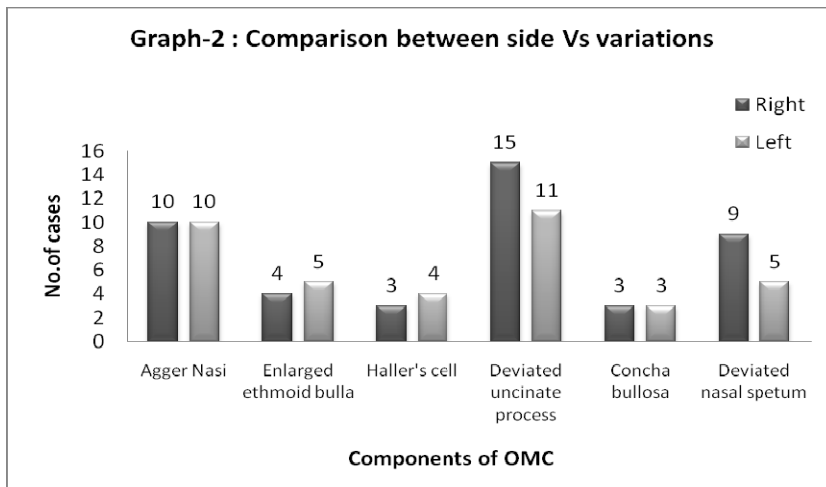
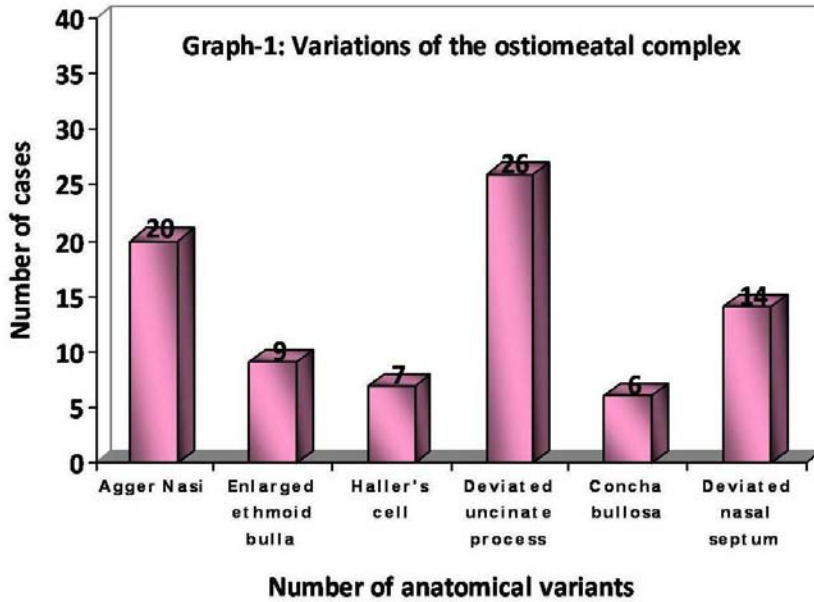
**Discussion**

Advances in the understanding of mucociliary drainage patterns and the patho-physiology of paranasal sinus inflammatory disease, coupled with the availability of high resolution CT and endoscopic instrumentation necessitate the clinician to have a precise knowledge of nasal sinus anatomy and of large number of anatomical variants in the region. Septal deviation is thought to laterally compress the middle concha and uncinete process into the infundibulum and thereby cause obstruction of the ostiomeatal unit (Davis *et al.*, 1996). Deviation of the nasal septum was found in 65% of cases in the present study. In other studies, this finding ranged from 14.1% to 80%: Dutra and Marchiori 14.1%, Kinusi *et al.*, 23.3%, Arslan *et al.*, 36%, Earwaker 44%, Pinas *et al.*, 80%, Maru 55.7% and 38% by Asruddin (Pinas *et al.*, 2000; Araujo *et al.*, 2004; Freitas *et al.*, 2008; Dua *et al.*, 2005). Davis *et al.* (1996) opined that septal deviation seems to be associated with more disease on the side of the deviation in adults.

The superior aspect of the uncinete tip may deviate laterally medially or anteriorly out of the middle meatus. In the present study, the curved uncinete was found in 65% of cases, medially bent process in 10 (25%) and laterally bent process in 16 (40%). It is comparatively higher than the earlier observations of Asruddin 2%, Maru *et al.*, 9.8%, Bolger 2.5%, Wanamaker 45%, Zinreich *et al.*, 3% and Lloyd 16% (Bolger *et al.*, 1991; Pinas *et al.*, 2000; Pruna, 2003; Araujo *et al.*, 2004; Dua *et al.*, 2005). Nayak *et al.* (2001) suggested that this variation has been implicating in narrowing of the infundibulum producing impaired sinus ventilation.

Fig 1. Coronal Imaging of the Ostiomeatal unit : Anatomical Variants observed





In coronal plane CT imaging, Kennedy and Zinreich noted the presence of agger nasi in nearly all patients evaluated. In the present study, the cell was detected in 50% cases. The incidence is less as compared to 98.5%

by Bolger, 88.5% by Maru, 15% by Gleeson; 86.7% by Tonai and Buba possibly due to the factors: 1) different definitions assigned to this anatomical variant; 2) the small size of the agger nasi cell might make its detection difficult in former studies. However, Asruddin reported a similar incidence of 48% (Davis *et al.*, 1996; Araujo *et al.*, 2004; Midilli *et al.*, 2005; Dua *et al.*, 2005; Freitas *et al.*, 2008).

The incidence of Haller's cell in the present study was 7/40 (17.5%) cases which correlates with the earlier studies of Llyod (15%), Gleeson (13%) and Dua (16%). Higher values were reported earlier by Bolger 45.9%, Maru 36%, Perez-Pinas 20%, Tonai and Baba 36% and Asruddin 28% (Davis *et al.*, 1996; Dua *et al.*, 2005; Caughey *et al.*, 2005; Freitas *et al.*, 2008). There was no difference in prevalence of Haller's cells between patients with or without sinusopathy. However Araujo *et al.* (2004) reported the larger cells are more likely related to tomographic alterations of maxillary sinuses. Davis *et al.* (1996) noted the cell is thought to cause chronic sinusitis by impinging on the ostium of the maxillary sinus and infundibulum by inhibiting ciliary function, leading to obstruction of the ostium.

The incidence of concha bullosa was 15% in the present study which is less as compared to the earlier reports of 53.6% by Bolger *et al.*, 42.6% by Maru *et al.*, 73% by Perez-Pinas *et al.*, 67% by Scribano *et al.*, 34 to 53% by Yousem, 30% by Wanamaker, 28% by Tonai and Baba, 28% by Asruddin and 36% by Zinreich *et al.* However it correlates with the earlier studies by Llyod (14%), Weinberger *et al.* (15%) and Dua *et al.* (16%) (Bolger *et al.*, 1991; Wang *et al.*, 1994; Jones, 2002; Freitas *et al.*, 2008). Davis *et al.* (1996) & Araujo *et al.* (2004) hypothesised that large concha bullosa would obstruct the ostia and cause sinusitis.

According to Som, mucosal abnormalities ranged from minimal mucosal thickening to total sinus opacification (Bolger *et al.*, 1991; Dua *et al.*, 2005). Maxillary sinus was the most commonly involved sinus (67.5%) in the present study, followed by ethmoidal sinus (32.5%) and frontal sinus (25%).

**Conclusion**

The most common anatomical variation associated with sinus disease was deviated uncinat process followed by agger nasi cells, enlarged ethmoidal bulla and Haller's cells. The least encountered variation was concha bullosa. Mucosal abnormalities associated with sinusitis were

predominantly seen in maxillary sinus, followed by ethmoidal and frontal sinuses respectively. Statistical comparison of ostiomeatal components did not show any significant variation between the two sexes or between the two sides. The CT scan should not be used exclusively to diagnose chronic sinusitis or to determine the need for surgery. Rather, it should be used to provide supplementary clinical data to the history and endoscopic exam, and assist in directing surgical treatment to the affected areas.

### References

1. Araujo SA, Martins P, Souza AS, Baracat EC and Nanni L (2004) The role of ostiomeatal complex anatomical variants in chronic rhinosinusitis. *Radiol. Bras.* 14, 1-9.
2. Bolger WE, Butzin CA and Parsons DS (1991) Paranasal sinus bony anatomic variations and mucosal abnormalities: CT analysis for endoscopic sinus surgery. *Laryngoscope.* 101, 56-64.
3. Caughey RJ, Jameson MJ, Gross CW and Han JK (2005) Anatomic risk factors for sinus disease: fact or fiction? *Am. J. Rhinol.* 19(4), 334-339.
4. Davis WE, Templer J and Parsons DS (1996) Anatomy of the paranasal sinuses. *Otolaryngol. Clin. North Am.* 29(1), 57-91.
5. Dua K, Chopra H, Khurana AS and Munjal M (2005) CT scan variations in chronic sinusitis. *Ind. J. Radiol. Imag.* 15(3), 315-320.
6. Freitas AP and Boasquevisque EM (2008) Anatomical variants of the ostiomeatal complex: tomographic findings in 200 patients. *Radiol. Bras. J.* 41(3).
7. Jones NS (2002) CT of the paranasal sinuses: a review of the correlation with clinical, surgical and histopathological findings. *Clin. Otol.* 27(1), 11-17.
8. Lloyd GA (1990) CT of the paranasal sinuses: study of a control series in relation to endoscopic sinus surgery. *J Laryngol Otol.* 104, 477-481.
9. Midilli R, Aladag G, Erginoz E, Karci B and Savas R (2005) Anatomic variations of the paranasal sinuses detected by computed tomography and the relationship between variations and sex. *Kulak Burun Bogaz Ihtis Derg.* 14(3-4), 49-56.
10. Nayak DR, Balakrishnan R and Murthy KD (2001) Functional anatomy of the uncinat process and its role in endoscopic sinus surgery. *Ind. J. Otol. Head Neck Surg.* 53(1), 27-31.
11. Pinas IP, Sabate J, Carmona A, Herrera CJ and Castellanos J (2000) Anatomical variations in the human paranasal sinus region studied by CT. *J. Anat.* 197, 221-227.
12. Polavaram R, Devaiah AK, Sakai O and Shapshay SM (2004) Anatomic variants and pearls- functional endoscopic sinus surgery. *Otolaryngol. Clin. N. Am.* 37, 221-242.
13. Pruna X (2003) Morpho-functional evaluation of ostiomeatal complex in chronic sinusitis by coronal CT. *Eur. Radiol.* 13(6), 1461-1468.
14. Sarna A, Hayman LA, Laine FJ and Taber KH (2002) Coronal imaging of the ostiomeatal unit: anatomy of 24 variants. *J. Comp. Assist. Tomogr.* 26(1), 153-157.
15. Scribano E, Ascenti G, Casio F, Racchiusa S, Salamone I (1993) Computerised tomography in the evaluation of anatomic variations of the ostiomeatal complex. *Radiol Med(Torino).* 86, 195-199
16. Stammberger H and Hawke M (1993) Essentials of endoscopic sinus surgery 1<sup>st</sup> ed. St. Louis: Mosby. pp:43.
17. Stammberger HR and Kennedy DW (1995) Paranasal sinuses: anatomic terminology and nomenclature. The anatomic terminology group. *Ann. Otol. Rhinol. Laryngol. Suppl.* 167, 7-16.
18. Tonai A, Baba S (1996) Anatomic variations of the bone in sinonasal CT. *Acta Otolaryngol Suppl.* 525, 9-13.
19. Wanamaker H (1996) Role of haller's cell in headache and sinus disease: a case report. *Otolaryngol Head Neck Surg.* 114, 324-327.
20. Wang R, Jiang S and Gu R (1994) The embryonic development of the ostiomeatal complex from 8 to 40 weeks. *Zhonghua Er Bi Yan Hou Ke Za Zhi.* 29(3), 131-133.
21. Yousem DM (1993) Imaging of the sinonasal inflammatory disease. *Radiol.* 188, 303-314.
22. Zinreich SJ, Albayaram S, Benson ML, Oliverio PJ (2003) The ostiomeatal complex and functional endoscopic surgery. In: Head and neck surgery. Som PM & Curtin HD (eds.), Mosby Inc, St Louis. pp:149-173.